EJCRIM
European Journal
of Case Reports
in Internal Medicine

WHEN CANCER THERAPY SUPPRESSES THE MARROW: IMMUNE-MEDIATED NEUTROPENIA FOLLOWING DURVALUMAB THERAPY IN CHOLANGIOCARCINOMA

Alaa Omari[1], Avshalom Leibowitz[1], Ana Belkin[1], Robert Huber[2]

[1] Department of Internal Medicine D, Sheba Medical Center, Ramat Gan, Israel
[2] Department of Pathology, Sheba Medical Center, Ramat Gan, Israel

Corresponding author's e-mail: alaa.omari@hotmail.com

Received: 10/10/2026
Accepted: 19/10/2026
Published: 27/11/2026

Conflicts of Interests: The Authors declare no conflict of interest.
Patient Consent: Written informed consent was obtained from the patient for publication of this case report, including the patient's clinical history and any accompanying images.
This article is licensed under a CC Attribution-NonCommercial-NoDerivatives 4.0 License

How to cite this article: Omari A, Leibowitz A, Belkin A, Huber R. When cancer therapy suppresses the marrow: immune-mediated neutropenia following durvalumab therapy in cholangiocarcinoma. EJCRIM 2026;13:doi:10.12890/2026_007584

ABSTRACT

Introduction: Hematologic immune-related adverse events associated with immune checkpoint inhibitors are uncommon but may be life-threatening. Severe neutropenia and agranulocytosis are particularly challenging to diagnose in patients receiving concomitant cytotoxic chemotherapy.

Case description: A 53-year-old woman with advanced cholangiocarcinoma developed febrile agranulocytosis with an absolute neutrophil count (ANC) of 0/µl after two cycles of gemcitabine, oxaliplatin, and durvalumab. Extensive infectious investigations were negative. Despite broad-spectrum antibiotics and granulocyte colony-stimulating factor, the ANC remained 0/µl for 20 days. High-dose corticosteroids produced no response. Bone marrow biopsy demonstrated severe granulocytic hypoplasia without malignant infiltration, with relative preservation of erythroid and megakaryocytic lineages, supporting an acquired immune-mediated marrow process. Treatment with cyclosporine followed by eltrombopag resulted in hematologic recovery, with ANC exceeding 1000/µl within 10 days of initiating cyclosporine.

Conclusion: Severe agranulocytosis should be considered in patients receiving immune checkpoint inhibitors who develop persistent neutropenia that is disproportionate to the expected effects of chemotherapy. Bone marrow evaluation may help distinguish immune-mediated marrow suppression from chemotherapy-related cytopenia. Early hematologic assessment and individualized treatment may be beneficial in steroid-refractory cases.

KEYWORDS

Durvalumab, agranulocytosis, neutropenia, immune checkpoint inhibitor, cholangiocarcinoma

LEARNING POINTS

- Profound and prolonged agranulocytosis during durvalumab-containing therapy should prompt consideration of an immune-mediated adverse event, even when concomitant chemotherapy provides an alternative explanation.
- Bone marrow examination demonstrating marked granulocytic depletion without malignant infiltration can help distinguish an immune-mediated marrow process from other causes of severe neutropenia.
- Steroid-refractory immune-mediated agranulocytosis may require escalation of treatment and early multidisciplinary involvement, with cyclosporine and eltrombopag representing potential therapeutic options in selected cases.

EFIM
European Federation of Internal Medicine

Publisher
smc media srl

INTRODUCTION

Immune checkpoint inhibitors (ICIs) have improved survival in several malignancies, including cholangiocarcinoma. The addition of the programmed death-ligand 1 (PD-L1) inhibitor durvalumab to gemcitabine–cisplatin chemotherapy significantly improved overall survival in advanced biliary tract cancers in the phase III TOPAZ-1 trial, establishing this combination as a new standard of care[1].

ICIs target key immune checkpoints, primarily programmed cell death protein 1 (PD-1)/programmed death-ligand 1 (PD-L1) and cytotoxic T-lymphocyte–associated protein 4 (CTLA-4), which normally maintain self-tolerance and prevent autoimmunity. PD-L1, expressed on tumour and immune cells, binds PD-1 on activated T cells to suppress their activity, allowing tumours to evade immune surveillance. PD-L1 blockade with antibodies such as durvalumab restores T-cell–mediated antitumor responses[2,3].

Although ICIs are generally well tolerated, their expanding use has revealed a broad spectrum of immune-related adverse events (irAEs) due to activation of the immune system. While most irAEs involve the skin, gastrointestinal tract, and endocrine organs, hematologic toxicities are infrequent (<1%). Among hematologic irAEs, the most frequently reported are immune thrombocytopenia and autoimmune haemolytic anaemia; neutropenia or agranulocytosis is less commonly documented, but carries a high risk of life-threatening infections and can be challenging to diagnose, as both cancer and cancer-directed therapies may cause cytopenia[4-6].

The pathophysiology of ICI-induced neutropenia remains incompletely understood. Proposed mechanisms include:

- Direct T-cell–mediated destruction of bone marrow myeloid precursors (aplastic-like picture).
- Autoantibody-mediated peripheral destruction of mature neutrophils.
- Dysregulated cytokine signalling leading to marrow suppression.

Most cases of ICI-induced neutropenia have been associated with PD-1 inhibitors (nivolumab, pembrolizumab)[2,7,8]. Reports linked specifically to PD-L1 inhibitors, such as durvalumab, remain extremely rare in the literature. With the increasing use of durvalumab in biliary tract cancers and other malignancies, recognition of this potential complication is crucial for early diagnosis and prompt management.

Here, we present a case of a patient with advanced cholangiocarcinoma who developed profound neutropenia following durvalumab in combination with chemotherapy. This report highlights the importance of recognizing hematologic irAEs as potential complications of PD-L1 blockade, differentiating them from chemotherapy-induced cytopenia, and instituting timely immunosuppressive therapy.

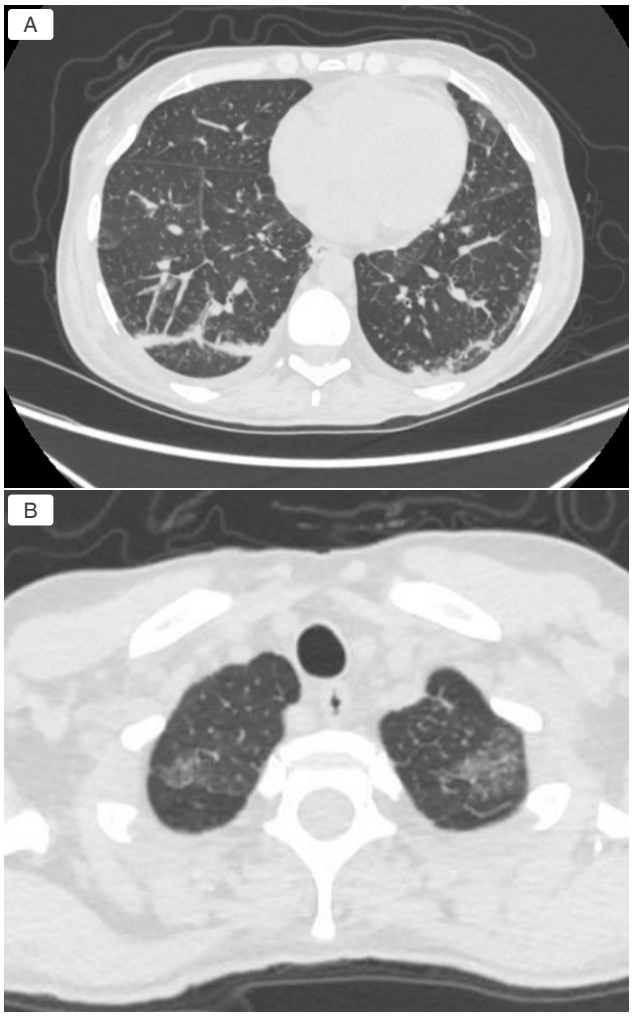

Figure 1. Chest computed tomography scan. A) Axial chest CT image demonstrating bilateral patchy ground-glass and fine reticular opacities in the upper lobes; B) axial CT image of the chest demonstrating bilateral patchy ground-glass and reticular opacities, with mild bibasilar linear atelectatic changes.

CASE DESCRIPTION

A 53-year-old female with a recent diagnosis of cholangiocarcinoma (June 2025) presented in September 2025 with fever and profound neutropenia (absolute neutrophil count [ANC] 0/µl). Her medical history was notable for hypothyroidism, heavy smoking, bulimia nervosa, and anxiety. Chronic medications included anxiolytics (venlafaxine, pregabalin, desloratadine), analgesics (fentanyl patch, oxycodone, acetaminophen, naloxone), levothyroxine, a beta-blocker (propranolol for hand tremor), and supplements (folic acid, vitamin D). Olanzapine had been initiated in June 2025 for nausea.

She received gemcitabine plus oxaliplatin every two weeks, with the last dose on August 17, 2025, and durvalumab on July 20 and August 17, 2025.

On September 1, 2025, she was admitted with fever (38.1°C) and agranulocytosis (ANC 0/µl). Empiric piperacillin–tazobactam and daily granulocyte colony-stimulating factor (G-CSF) were initiated, but ANC remained persistently at zero for 20 days.

During this period, she had a chest and sinus computed

Date	Event	Intervention	ANC (cells/µl)
20/07/25	Cycle 1 durvalumab + chemotherapy	—	2200
17/08/25	Cycle 2 durvalumab + chemotherapy	—	2100
01/09/25	Day 1 of hospitalization with febrile neutropenia	Started piperacillin–tazobactam + G-CSF	0
05/09/25	Persistent febrile neutropenia	High-dose corticosteroids	0
10/09/25	Completed BAL	Escalated to voriconazole + meropenem; corticosteroids stopped	0
11/09/25	Bone marrow biopsy		0
12/09/25	Diagnosis of aplasia	Cyclosporine started	0
17/09/25	Persistent neutropenia	Eltrombopag added to cyclosporine	0
20/09/25	Refractory neutropenia	Stopped voriconazole and meropenem, started levofloxacin and fluconazole	210
22/09/25	Hematologic recovery	Stopped levofloxacin and fluconazole, complete cyclosporine and eltrombopag for 2 months	>1000

Table 1. *Clinical course, interventions, and absolute neutrophil count trends.*
Abbreviations: G-CSF, granulocyte colony-stimulating factor; BAL, bronchoalveolar lavage.

tomography (CT) scan which revealed new small pleural effusions, minimal pericardial effusion, multiple lower-lobe nodular opacities suggestive of infection or inflammation, and subtle upper-lobe ground-glass changes *(Fig. 1)*. Previously noted metastatic pulmonary lesions had regressed. Bronchoalveolar lavage (BAL) and an extensive infectious workup—including blood and urine cultures, cytomegalovirus, human immunodeficiency virus, parvovirus B19, galactomannan, and BAL cultures—were all negative. Immune profiling was largely unremarkable, except for mildly elevated myeloperoxidase - specific antineutrophil cytoplasmic antibody. Recurrence of fever despite antibiotics prompted escalation to meropenem and voriconazole.

Given the persistent, profound neutropenia without an identifiable infectious etiology, immune-mediated neutropenia was suspected. On September 5, 2025, she received high-dose corticosteroids (methylprednisolone 125 mg daily for 3 days, followed by a single 500 mg pulse) without improvement.

A bone marrow biopsy on September 11, 2025 showed severe granulocytic hypoplasia without malignant infiltration, consistent with an acquired aplastic process *(Fig. 2)*. Following haematology consultation, cyclosporine was initiated on September 12, 2025, followed by eltrombopag on September 17, 2025. By September 22, 2025, ANC had risen above 1000/µl, marking hematologic recovery.

A detailed timeline of therapy, interventions, and ANC recovery is provided in *Table 1*.

DISCUSSION

ICIs have transformed the treatment of multiple malignancies, including biliary tract cancers. Hematologic irAEs are exceedingly rare (<1%) but can be life-threatening when they occur. Neutropenia and agranulocytosis represent some of the most severe complications due to infection risk and poor outcomes.

The precise mechanisms behind ICI-associated neutropenia remain incompletely defined but several plausible pathways have been proposed. First, T-cell–mediated marrow attack may occur as ICIs unleash autoreactive cytotoxic T cells that target hematopoietic progenitors, particularly myeloid precursors, leading to selective granulocytic aplasia. Bone marrow biopsies often demonstrate profound depletion of granulocytic precursors with relative preservation of erythroid and megakaryocytic lineages, consistent with this mechanism. Second, autoantibody-mediated peripheral destruction has been suggested, although findings are inconsistent[9]. Third, cytokine-mediated suppression via interferon-γ and tumour necrosis factor-α may impair granulopoiesis or induce apoptosis of myeloid progenitors. Finally, there appears to be an overlap with immune-mediated marrow aplasia, as some patients present with isolated neutropenia, while others develop a broader aplastic picture[10-12].

Published literature describes variable timing of ICI-related neutropenia, from after a single dose to several treatment cycles, with heterogeneous therapeutic responses. Most documented cases involve PD-1 inhibitors (nivolumab,

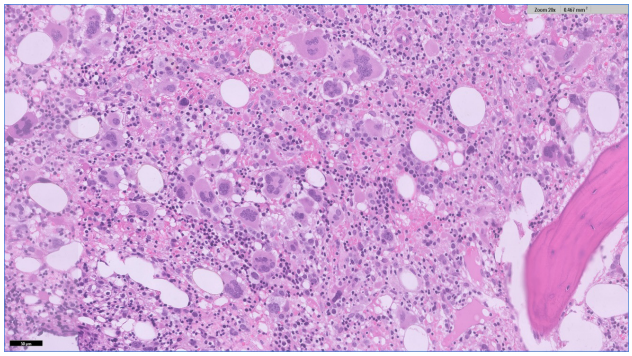

Figure 2. *Bone marrow aspirate.*

pembrolizumab), whereas PD-L1-related cases are exceedingly rare, underscoring the importance of our observation.

In a systematic review, Delanoy et al. identified 35 patients with hematologic irAEs across PD-1/PD-L1 inhibitors, with neutropenia accounting for a minority but being associated with high morbidity and mortality, including deaths from febrile neutropenia[10].

Similarly, a meta-analysis of severe neutropenia following ICIs highlighted both diagnostic and therapeutic challenges, with many cases requiring discontinuation of therapy, administration of G-CSF, and immunosuppressive treatment[12]. A comparable pattern was observed in the case series by Jalil et al., whose review of approximately 20 published cases underscored that ICI-induced neutropenia can occur with various agents, including PD-1, PD-L1, and CTLA-4 inhibitors, and may persist even after discontinuation of therapy. The authors also noted variable responses to corticosteroids, intravenous immunoglobulin, and G-CSF, with some patients requiring additional immunosuppressive therapy such as cyclosporine or antithymocyte globulin[2]. Importantly, early recognition and prompt treatment are crucial to prevent potentially fatal infectious complications.

In our patient, profound and persistent neutropenia developed shortly after two cycles of durvalumab with gemcitabine and oxaliplatin. Despite the potential contribution of chemotherapy, the absence of granulocytic precursors with preserved erythroid and megakaryocytic lineages, alongside the lack of marrow infiltration, supported an immune-mediated etiology rather than a direct cytotoxic effect. The lack of response to G-CSF and corticosteroids, followed by a robust recovery after the introduction of cyclosporine and eltrombopag, further supports an immune-driven mechanism. Notably, cyclosporine alone did not achieve complete hematologic recovery until eltrombopag was added, suggesting a synergistic effect on marrow recovery.

The temporal relationship between durvalumab administration and neutropenia onset, coupled with exclusion of alternative aetiologies (infection, drugs, chemotherapy, nutritional deficiencies, or malignant infiltration), strengthens the causal association. Interestingly, simultaneous regression of metastatic pulmonary lesions was observed, suggesting that the same immune activation contributing to tumour response may have precipitated marrow autoimmunity, a phenomenon previously described in other ICI-induced cytopenia.

Management of ICI-related neutropenia requires a multidisciplinary approach. Initial measures include ICI discontinuation, empirical broad-spectrum antibiotics, and G-CSF for febrile neutropenia. Corticosteroids remain first-line immunosuppression; however, in steroid-refractory cases, additional agents such as cyclosporine, mycophenolate mofetil, or antithymocyte globulin may be required. In our case, combination immunosuppression with cyclosporine and eltrombopag resulted in rapid and sustained hematologic recovery, emphasizing the importance of early immunomodulatory therapy in resistant presentations.

This case expands the limited literature on durvalumab-induced immune-mediated neutropenia, highlighting that this rare complication can occur even in combination chemotherapy settings. Clinicians should maintain vigilance for immune-mediated marrow suppression in patients with unexplained cytopenia during or after ICI therapy. Early recognition, prompt diagnostic evaluation (including bone marrow biopsy), and timely immunosuppressive treatment are crucial to improve outcomes. Further research is warranted to elucidate underlying mechanisms and define optimal management strategies for this rare but serious irAE.

As with most case reports, definitive causality cannot be established. Concomitant chemotherapy (gemcitabine and oxaliplatin) and olanzapine may have contributed to neutropenia. However, the bone marrow findings (isolated granulocytic aplasia with preserved erythroid and megakaryocytic lineages), temporal relationship with durvalumab administration, lack of response to G-CSF, and prompt recovery following immunosuppressive therapy strongly support an immune-mediated mechanism related to PD-L1 blockade.

CONCLUSION

Immune-mediated neutropenia is a rare but potentially life-threatening complication of ICI therapy. This case illustrates that durvalumab, even when administered in combination with chemotherapy, can trigger profound granulocytic aplasia. Recognition requires a high index of suspicion, especially in patients with persistent febrile neutropenia unresponsive to antibiotics, G-CSF, and corticosteroids. Bone marrow evaluation can provide critical diagnostic insight, distinguishing immune-mediated cytopenia from chemotherapy-induced suppression or marrow infiltration. Immunosuppressive therapy, such as cyclosporine and eltrombopag, may lead to rapid hematologic recovery, highlighting the importance of early intervention.

Clinicians should be aware of this rare toxicity to mitigate infection risk and optimize patient outcomes. Reporting additional cases will be vital to improving understanding, guiding management, and shaping future treatment algorithms for ICI-related hematologic toxicities.

REFERENCES

1. Oh DY, Ruth He A, Qin S, Chen LT, Okusaka T, Vogel A, et al. Durvalumab plus Gemcitabine and Cisplatin in Advanced Biliary Tract Cancer. NEJM Evid. 2022;1(8):EVIDoa2200015. doi: 10.1056/EVIDoa2200015.
2. Jalil A, Zaffar J, Waqas A, Butt S. Isolated Neutropenia Due to Immune Checkpoint Inhibitors. Cureus. 2023;15(9):e45674. doi: 10.7759/cureus.45674.
3. Lee HT, Lee JY, Lim H, Lee SH, Moon YJ, Pyo HJ, et al. Molecular mechanism of PD-1/PD-L1 blockade via anti-PD-L1 antibodies atezolizumab and durvalumab. Sci Rep. 2017;7(1):5532. doi: 10.1038/s41598-017-06002-8.
4. Grinsztejn E, Perez JA, DeSouza SI. Immunotherapy-Related Hematological Adverse Events: Incidence and Outcomes. Blood [Internet]. 2023;142(Supplement 1):2368. doi: 10.1182/blood-2023-180370.
5. Petrelli F, Ardito R, Borgonovo K, Lonati V, Cabiddu M, Ghilardi M, et al. Haematological toxicities with immunotherapy in patients with cancer: a systematic review and meta-analysis. Eur J Cancer. 2018;103:7-16. doi: 10.1016/j.ejca.2018.07.129.
6. Kitamura Y, Shimizu S, Kuroda S, Honmyo N, Nakano R, Sakai H, et al. Durvalumab induced immune-related agranulocytosis after conversion surgery in a patient with intrahepatic cholangiocarcinoma: a case report. Front Immunol. 2025 Jul;16:1610190. doi: 10.3389/fimmu.2025.1610190.
7. Kalaci E, Ürün Y. Nivolumab-induced immune-related neutropenia in a renal cell carcinoma patient. J Oncol Pharm Pract. 2023;29(7):1797-1801. doi: 10.1177/10781552231186748.
8. Naqash AR, Appah E, Yang LV, Muzaffar M, Marie MA, Mccallen JD, et al. Isolated neutropenia as a rare but serious adverse event secondary to immune checkpoint inhibition. J Immunother Cancer. 2019;7(1):169. doi: 10.1186/s40425-019-0648-3.
9. Boegeholz J, Brueggen CS, Pauli C, Dimitriou F, Haralambieva E, Dummer R, et al. Challenges in diagnosis and management of neutropenia upon exposure to immune-checkpoint inhibitors: meta-analysis of a rare immune-related adverse side effect. BMC Cancer. 2020;20(1):300. doi: 10.1186/s12885-020-06763-y.
10. Delanoy N, Michot JM, Comont T, Kramkimel N, Lazarovici J, Dupont R, et al. Haematological immune-related adverse events induced by anti-PD-1 or anti-PD-L1 immunotherapy: a descriptive observational study. Lancet Haematol. 2019;6(1):e48-e57. doi: 10.1016/S2352-3026(18)30175-3.
11. Michot JM, Lazarovici J, Tieu A, Champiat S, Voisin AL, Ebbo M, et al. Haematological immune-related adverse events with immune checkpoint inhibitors, how to manage? Eur J Cancer. 2019;122:72-90. doi: 10.1016/j.ejca.2019.07.014.
12. Kroll MH, Rojas-Hernandez C, Yee C. Hematologic complications of immune checkpoint inhibitors. Blood. 2022;139(25):3594-3604. doi: 10.1182/blood.2020009016.